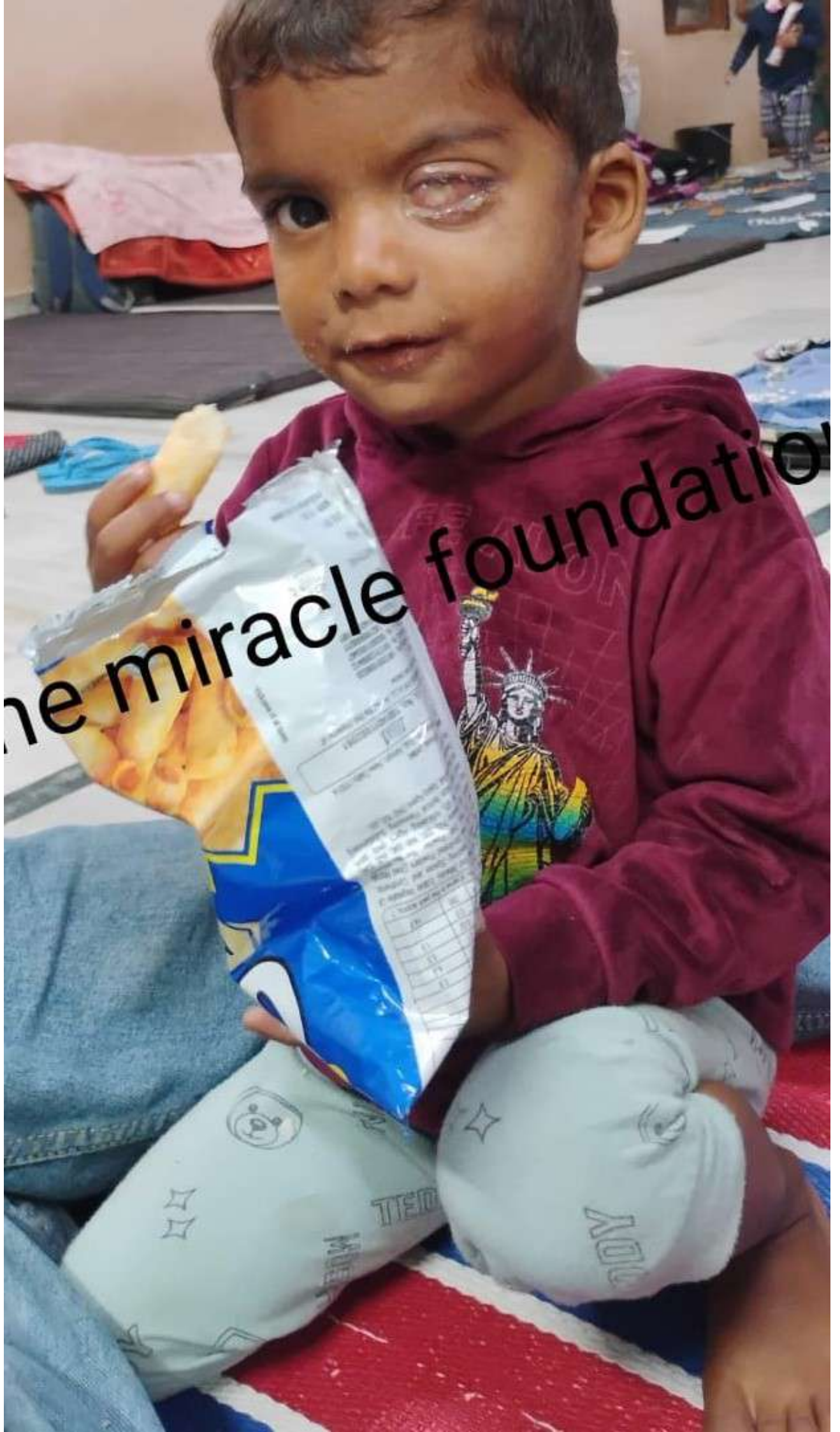



the miracle foundation

Postgraduate Institute of Medical Education and Research Chandigarh  
 Department of Pediatric Medicine  
 HAEMOGRAM REPORT

Patient Name: Anant Veer  
 Age/Sex: 3 Y/M  
 Specimen: Blood  
 Ward/OPD: Ophthalmology(Eye)-Unit 2  
 CR number: 202504642545  
 Lab ID No: 101/  
 Requisition Date: 30/10/2025

	Result	Reference Range
Haemoglobin (gm/dL)	10.8	11.5 - 13.5
HCT (%)	33.7	34 - 40
RBC Count ( $\times 10^6$ /L)	4.39	3.9 - 5.3
Mean Cell Volume (fl)	76.8	75 - 87
MCH (pg)	24.6	24 - 30
MCHC (%)	32.0	31 - 37
RDW (CV %)	17.5	11.0 - 14.5
Reticulocyte Count (%)		10 - 27
ESR (mm in 1 <sup>st</sup> hour)		
Fragment RBC Count (%)		
Platelet Count ( $\times 10^3$ /L)	509	200 - 450
MPV (fl)	10.5	6 - 11
TLC ( $\times 10^9$ /L)	18.22	5.5 - 15.5
Macrocytes (%)		
Microcytes (%)		

Differential Leucocyte Count		Result	Reference Range
Neutrophils (%)	69.5	27 - 54	15 - 85
Lymphocytes (%)	22.8	40 - 60	30 - 95
Eosinophils (%)	7.2	0 - 6	0.1 - 1
Monocytes (%)	7.2	2 - 11	0.2 - 1
Basophils (%)	0.3	0 - 1	
Blasts (%)			0 - 0.06
Promyelocytes (%)			
Myelocytes (%)			
Metamyelocytes (%)			
Immature Granulocytes (%)	0.4	0 - 0.6	
nRBC (per 100 WBC)	0.0		

Advice

Remarks

Validated On

30-10-25 01:08 PM

Validated By

Nand Lal(Jr.Lab Technician)

The miracle foundation



AD/4418

CR No. : 2025 0464 2545 Date : 29-10-2025

: 2025 0464 2545 Date : 29-10-2025

: ANANT VEER

: 3 Y/M

Category : General

Name: Geerat Singh

: Dept. MEDICINE

: Rajasthan India

Ref: Ophthalmology (Eye)

Ref: Retinoblastoma Clinic/US

: 220

Serial No : 1

: AFORR#1370

Report (Ref): 10/

**PROVISIONAL DIAGNOSIS**

तारीख व हस्ताक्षर DATE & INITIALS	बताई गई जांचें व उपचार TREATMENT AND INVESTIGATIONS ORDERED
--------------------------------------	--

SUPPLY FOLLOWING DRUGS OR  
 EQUIVALENT GENERIC DRUGS

*The miracle foundation*

क्रेडिट @ Mass 12304  
 Same 6m 1/2 yr

UIG } - Showe Rb.  
 MRB }

OP ~~class~~ - Rb. class  
 (220) (219)

(212)  
 @ 019

पी.जी.आई में हुए जन्म तथा मृत्यु के प्रमाण पत्र के लिए एम.आर.डी. विभाग में सम्पर्क करें

DATE & INITIALS  
 बतलाई गई जांचें व उपचार  
 TREATMENT AND INVESTIGATIONS ORDERED

29/10/15

Adv USG (2/2) (L)

to look for vchans  
 calcification & R/L

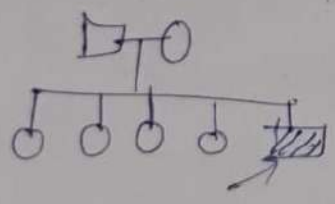
gentle/as comes already perforated

23

RB file please

Dr. Pooja

5th history = FT/NVD/CMB/  
 NO/1/0 ICU stay.



USG done in 2015

(L) Ruptured mass dispersed fully in vitreous  
 coming anteriorly

DATE & INITIALS  
 बतलाई गई जांचें व उपचार  
 TREATMENT AND INVESTIGATIONS ORDERED

31/10/15

SUPPLY FOLLOWING DRUGS OR EQUIVALENT GENERIC DRUGS

MRI done outside in April 2015  
 - large multilobulated intraocular soft tissue mass in left side of orbit & periorbital fat stranding in R.S.

Refer to POC clinic for chemotherapy & metastatic workup.

(L) eyedrop. Toba (6)  
 Loxan ointment (3)

MA after POC clinic

§

Referring Dr. Satyanarayan  
 Part Scanned  
 Age / Sex : 3 / M  
 Date : 3/10

Dr. Navneet Garg  
 DMRD, DNB  
 Consultant Radiologist



Postgraduate Institute of Medical Education & Research  
 Chandigarh

Department of Pediatric Medicine

Laboratory : Pediatric Biochemistry Lab  
 CR No : 202504642545  
 Patient Name : Anant Veer  
 Dept-Unit : Ophthalmology(Eye)-Unit 2  
 Ward/OPD : OPD  
 Lab-Sample No. : 0126  
 Diagnosis :

Sample : Blood

Age/Sex : 3 Yr/M  
 Req. Date : 30/10/2025  
 Clinician :

Investigation	Result	Unit	Standard Ranges
ALP	213	U/L	145 - 420
Albumin	4.3	g/dL	4 - 4
Bilirubin (conjugated)	0.09	mg/dL	- 3
ALT	11	U/L	2 - 41
Protein total	7.1	g/dL	6.4 - 8.3
AST	28	U/L	2 - 40
Bilirubin (total)	0.50	mg/dL	0.2 - 1.2
Sodium	136	mmol/L	135 - 145
Potassium	4.12	mmol/L	3.5 - 5
Chloride	104	mEq/L	96 - 106
Calcium	10.0	mg/dl	8.8 - 10.2
Uric Acid	4.1	mg/dl	3.4 - 7.0
Urea	19	mg/dL	10 - 50
Creatinine	0.34	mg/dL	0.5 - 1.2

The miracle foundation

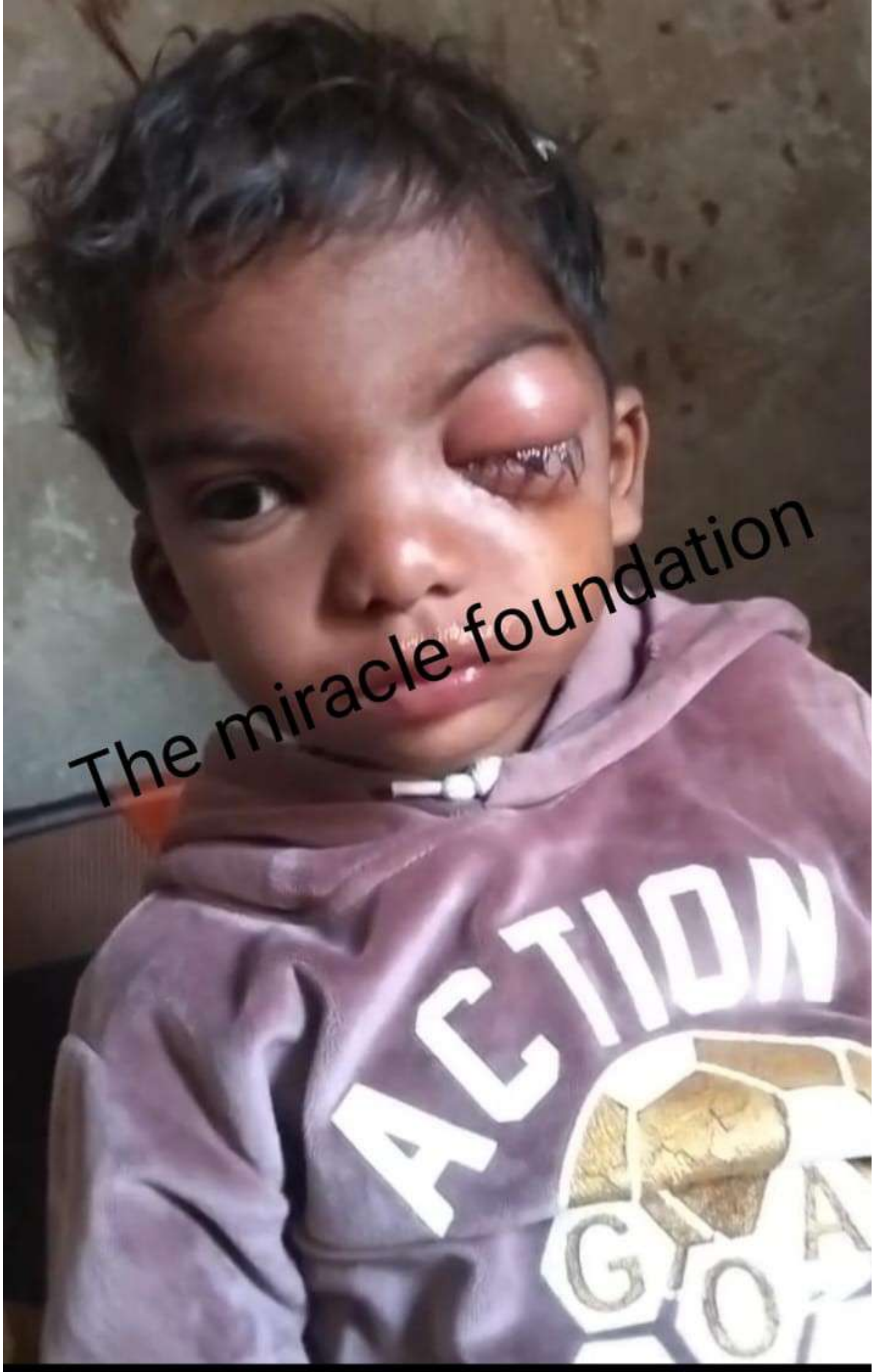Shot on moto g34 5G

~Jass@

7 Nov 2025

The miracle foundation

ACTION  
GOAL





भारत सरकार

Government of India



जगजीत सिंह

Jagjeet Singh

माता : मनजीत कौर

Mother : Manjeet Kaur

जन्म तिथि / DOB : 01/01/1992

पुरुष / Male



5334 2427 3138

आधार - आम आदमी का अधिकार

DEPARTMENT OF RADIODIAGNOSIS & IMAGING  
P.G.I.M.E.R., CHANDIGARH  
ULTRASOUND REPORT

Name:	ANANT VEER			Age:	3 y	Sex:	M
CR No:	202504642545	Acc No:	PG613621	Ward / OP:	OP		
Ref By:	Default Doctor (DefDoc)	Ph. No.:		Study Date:	03/11/2025 9:18AM		

**\*\* REPORT DETAILS \*\***  
**ULTRASOUND WHOLE ABDOMEN**

**Findings:**

- Liver is normal in size ( 10cm), outline and echotexture. No focal lesion seen. IHBR not dilated. Hepatic veins and portal vein are normal.
- Gall bladder is normal in distension and echotexture. CBD is not dilated.
- Spleen is normal in size ( 6.7cm), outline and echotexture. No focal lesion seen.
- Pancreas is normal in bulk and echotexture, in head and body, tail obscured. No focal lesion seen. MP is not dilated.
- Both kidneys are normal in site, size, outline and echotexture. No focal lesion seen. Bilateral PC is not dilated.
- No evidence of significant retroperitoneal lymphadenopathy seen.
- Urinary bladder is normal in distension and echotexture.
- No pelvic mass or lymphadenopathy seen.
- Bowel loops appear normal.
- No ascites seen.

**Impression:** Normal study.

Prepared by: Dr. Kanupriya Arora (Senior Resident)

Report Status: Validated /Dr. Kanupriya Arora

Dr. Kanupriya Arora

Senior Resident

\* This is an electronically verified report : Does not require a signature.

\*\*\*\*\*End Of Report\*\*\*\*\*

moto g34 5G



POST GRADUATE INSTITUTE OF MEDICAL EDUCATION & RESEARCH.  
SECTOR 12, CHANDIGARH  
POSTGRADUATE INSTITUTE OF MEDICAL EDUCATION & RESEARCH  
TEST RECEIPT  
CHANDIGARH-160012 (INDIA)

ORIGINAL

DATE & TIME : 03/11/2025 10:56:49

RECEIPT NO. : 2251401184/1

CATEGORY : GENERAL

CR No. : 202504642545

WARD : OPHTHALMOLOGY(EYE)

NAME : ANANT VEER

AGE/SEX : 3 YR/MALE

DESCRIPTION

PET SCAN - SINGLE REGION (NUCLEAR MEDICINE)

DESCRIPTION	RATE (Rs.)	QTY	AMOUNT (Rs.)
PET SCAN - SINGLE REGION (NUCLEAR MEDICINE)	3000	1	3000.00
TOTAL AMOUNT			3000.00

RUPEES (IN WORD) : THREE THOUSAND RUPEES ONLY  
PAYMENT MODE / AMOUNT : CASH/3000 RUPEES

NANPREET KAUR (POS 16 NO 05)

The miracle foundation

7 Nov 2025, 9:2

GST No: 04AEJFS6787H3ZF

GST INVOICE

D.L.No: RLF20CH2025000115, RLF21CH2025000113

SHIV GOYAL CHEMIST

SHOP NO. 4, NEW SHOPPING COMPLEX, PGIMER, SECTOR-12, CHANDIGARH.

Ph. 8295619656 sgo4nsc@gmail.com

NAME: ANNANTVEER

CASH MEMO NO.: 7901

DOCTOR/INSTITUTE NAME : P.G.I.M.E.R CHANDIGARH

DATE : 04/11/2025

CR.NO. :

S.NO	PARTICULARS	HSNCode	MFD.	PACK	QTY	BATCH No.	EXP.	GST%	RATE	AMOUNT	DIS%	NETAMT*
1.	2480   DOTAREM INJ 10ML	30063000	GUERBE	10 ML	1	24GD1232	11/27	5.00	2480.00	2480.00	43.50	1401.20

The miracle foundation

SHIV GOYAL CHEMIST  
PAID  
SHOP No. 4, NSC, PGIMER, SEC-12, CHD

Please get your medicine checked from doctor before use.

INCL. GST DETAILS :

1334.47 X 5 % = 66.72 ,

USER

CGST : 33.36  
UTGST: 33.36

TOTAL AMOUNT : 2480.00  
LESS 1078.80  
Net Amt.(R/0): 1401.00

Amount in Words: One Thousand Four Hundred One Only

For sale return of goods provide original invoice copy are mandatory.

All disputes are subject to chandigarh jurisdiction.

Price wrongly charged by oversight will be refunded.

Return of goods will be accept only within 30 days from billing date.


(Computer Generated Invoice)

E & O.E

For SHIV GOYAL CHEMIST

Pharmacist/Qualified person

SHIV GOYAL



on moto-g3455G  
7 NOV 2025, 9:22 am

दिनांक  
DATE

उपचार व प्रगति  
Treatment and Progress

04/11/25

PHD

202504642545

Anant veer, 34/m

Δ.) Rt eye FORB.

CEMRI brain & PET CT  
did 04/11/25.

Plan:

- To do CSF analysis &  
cytology of CSF & menow

The miracle foundation

POC registration on 07/11/25  
& 30F-1

7/11/25  
Kindly register in  
POC drive → Dr. Anita  
Kumar (GREEN FILE)

(Dr. Anjumudha  
SR Phd)

POST GRADUATE INSTITUTE OF MEDICAL EDUCATION & RESEARCH.  
SECTOR 12, CHANDIGARH

TEST RECEIPT

DATE & TIME : 04/11/2025 10:20:15

RECEIPT NO. : 2251407046/1

CATEGORY : GENERAL

CR No. : 202504642545

WARD : OPHTHALMOLOGY(EYE)

NAME : ANANT VEER

AGE/SEX : 3 YR/M

DESCRIPTION

MRI (SINGLE REGION)(RADIOLOGY)

AMOUNT(Rs) QTY. AMOUNT(Rs.)

2500 1 2500.00

TOTAL AMOUNT 2500.00

RUPEES (IN WORD) : TWO THOUSAND FIVE HUNDRED RUPEES ONLY  
PAYMENT MODE / AMOUNT : CASH/2500 RUPEES

ANAN KUMAR (POS APC 10)

ORIGINAL



POSTGRADUATE INSTITUTE OF MEDICAL EDUCATION & RESEARCH

not on moto g34 5G

The miracle foundation

7 Nov

तारीख व हस्ताक्षर  
DATE & INITIALS

TREATMENT

TESTS ORDERED

CR No. 202504642545  
Anant Vohar 13 Y/M



SAMPLE NO.:

TESTS OR DRUGS

29/10/25

LT eye EORB(?)

5th child of mrm  
resident of Srikanth  
-ganagar.

Swelling & whitish  
discolouration of Lt  
eye globe for last  
1 1/2 yrs.

ऑनलाइन लैब रिपोर्ट वेबसाइट pgimer.edu.in/ors.gov.in  
Lab test reports are available on website pgimer.edu.in/ors.gov.in

# The miracle foundation

Exophthalmos with  
perforated Lt eye  
mass

MRI outside did sim back -  
? Extension of Lt optic N.

Adv: - CBC / WBC / CRP / USG abdomen  
& PET CT whole body  
MRI brain.

T/R @ POC (40/1418) on 07/11/25  
for POC registration / well being

कृप्या गीला कूड़ा हरे रंग के डिब्बे में डाले।  
सुखा कूड़ा नीले रंग के डिब्बे में डाले।

Dr. Animuddha  
SR PHO